

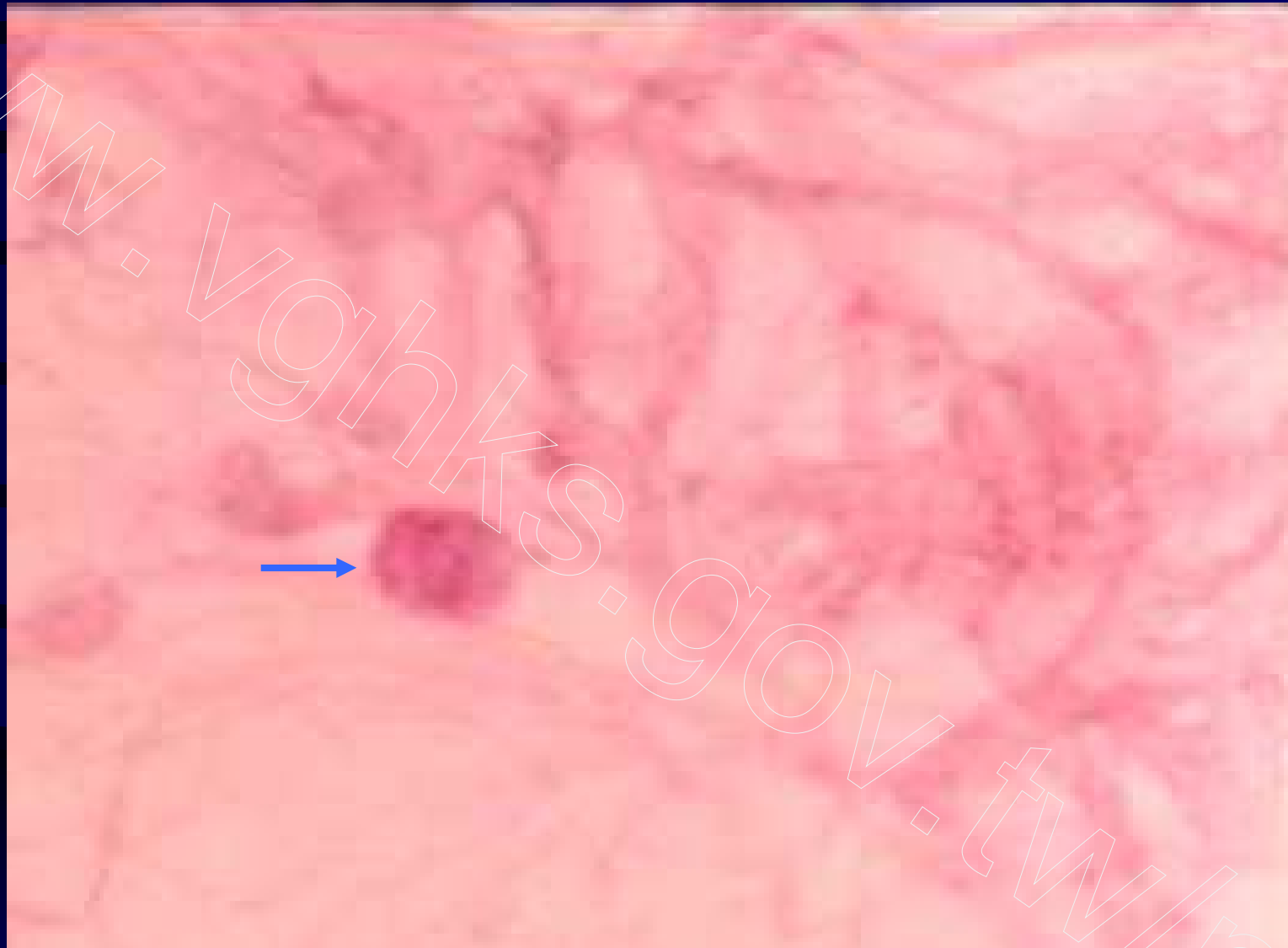Fig 71. Diabetic retinopathy, microaneurysm in retina capillary, PAS

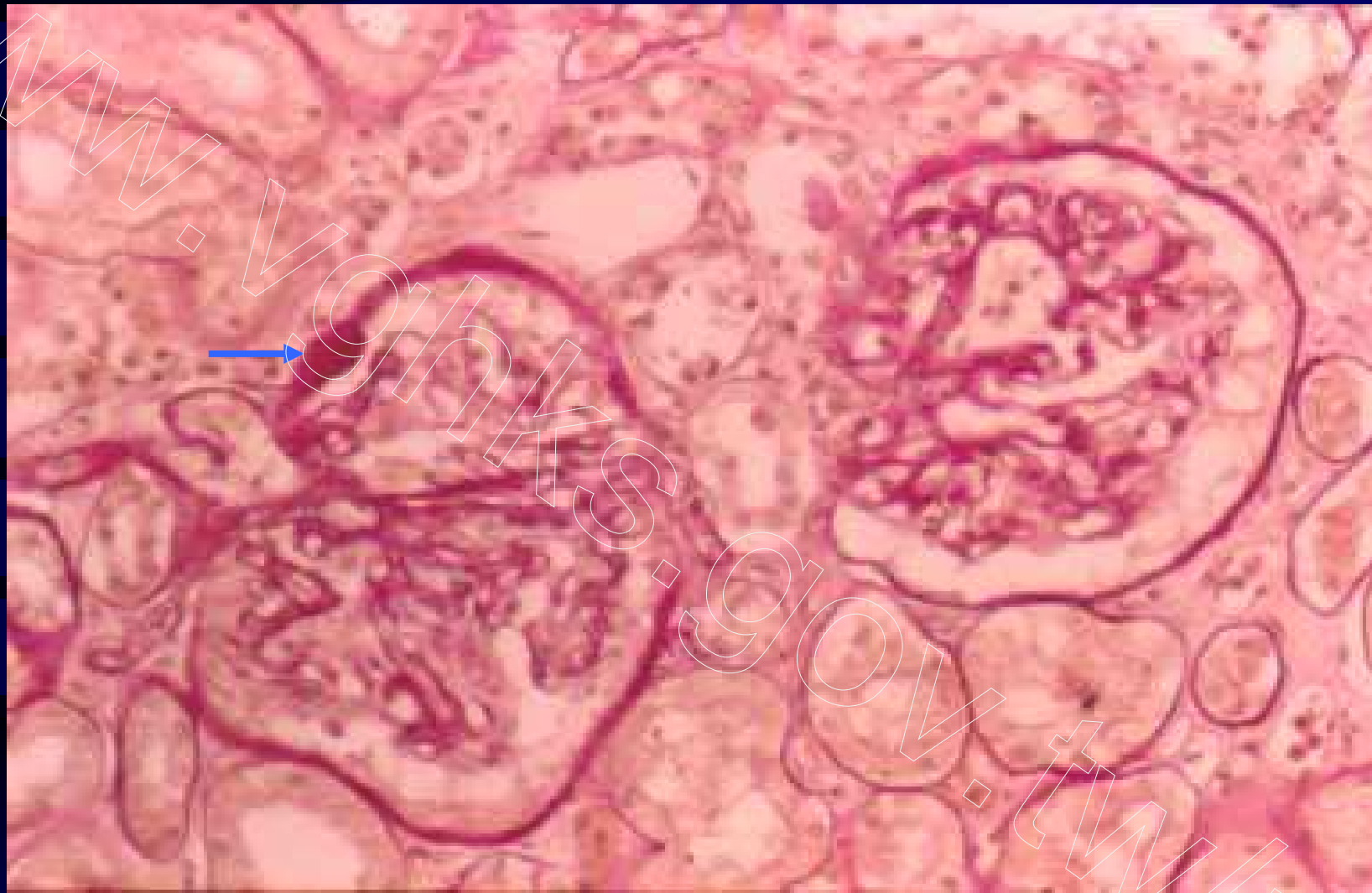

Fig 72. Diabetic glomerulosclerosis, Capsular drop, PAS

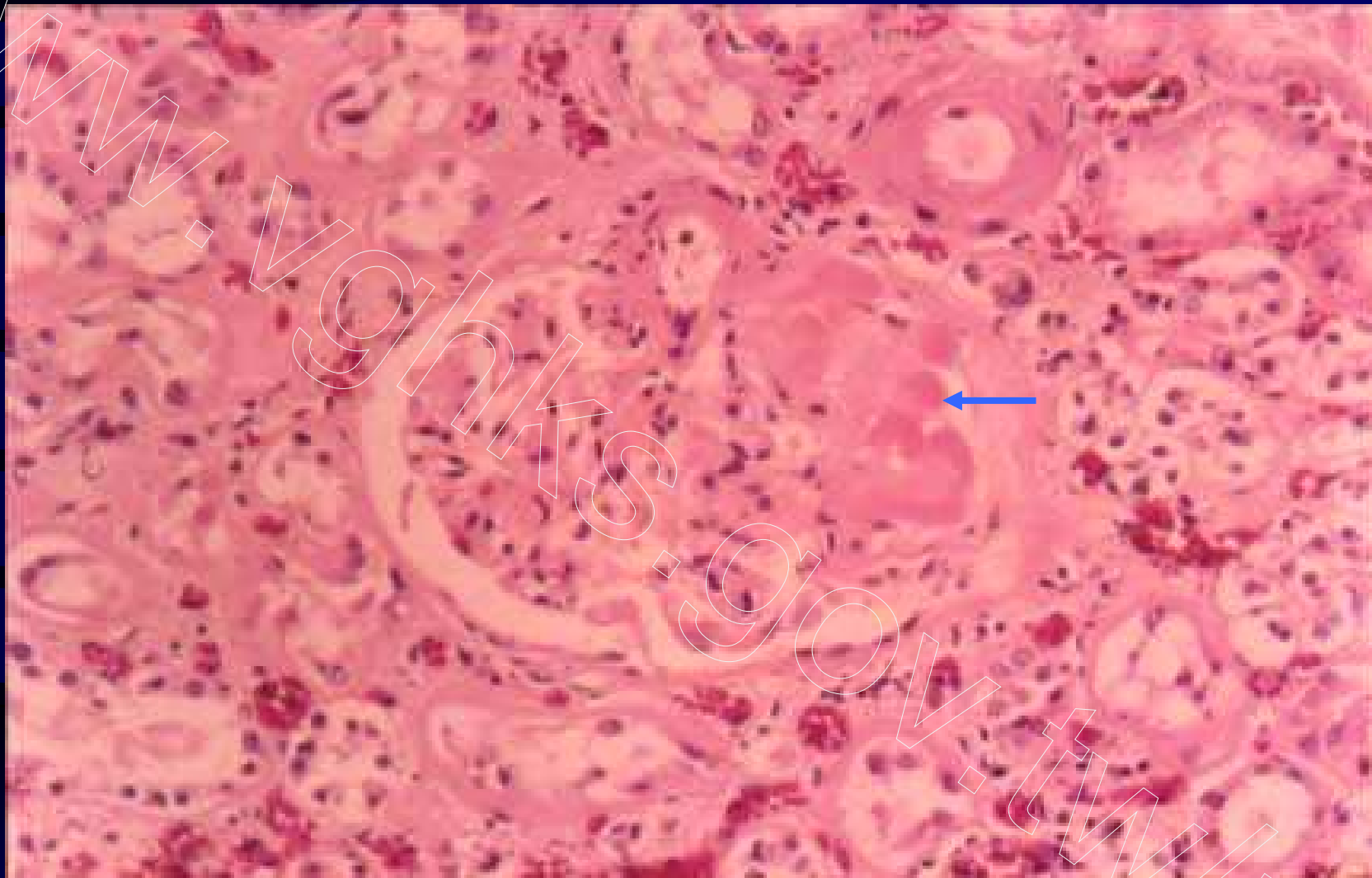
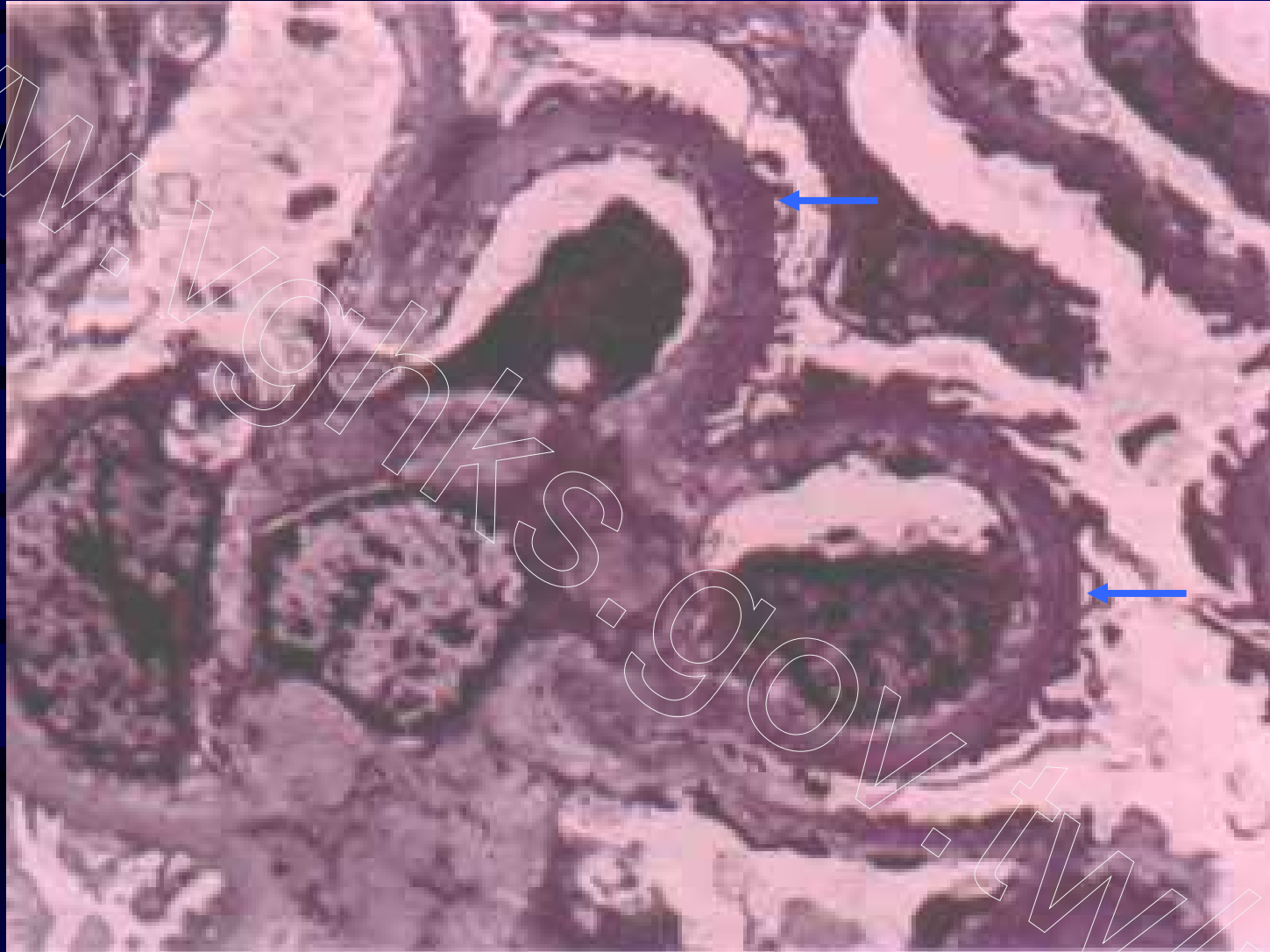
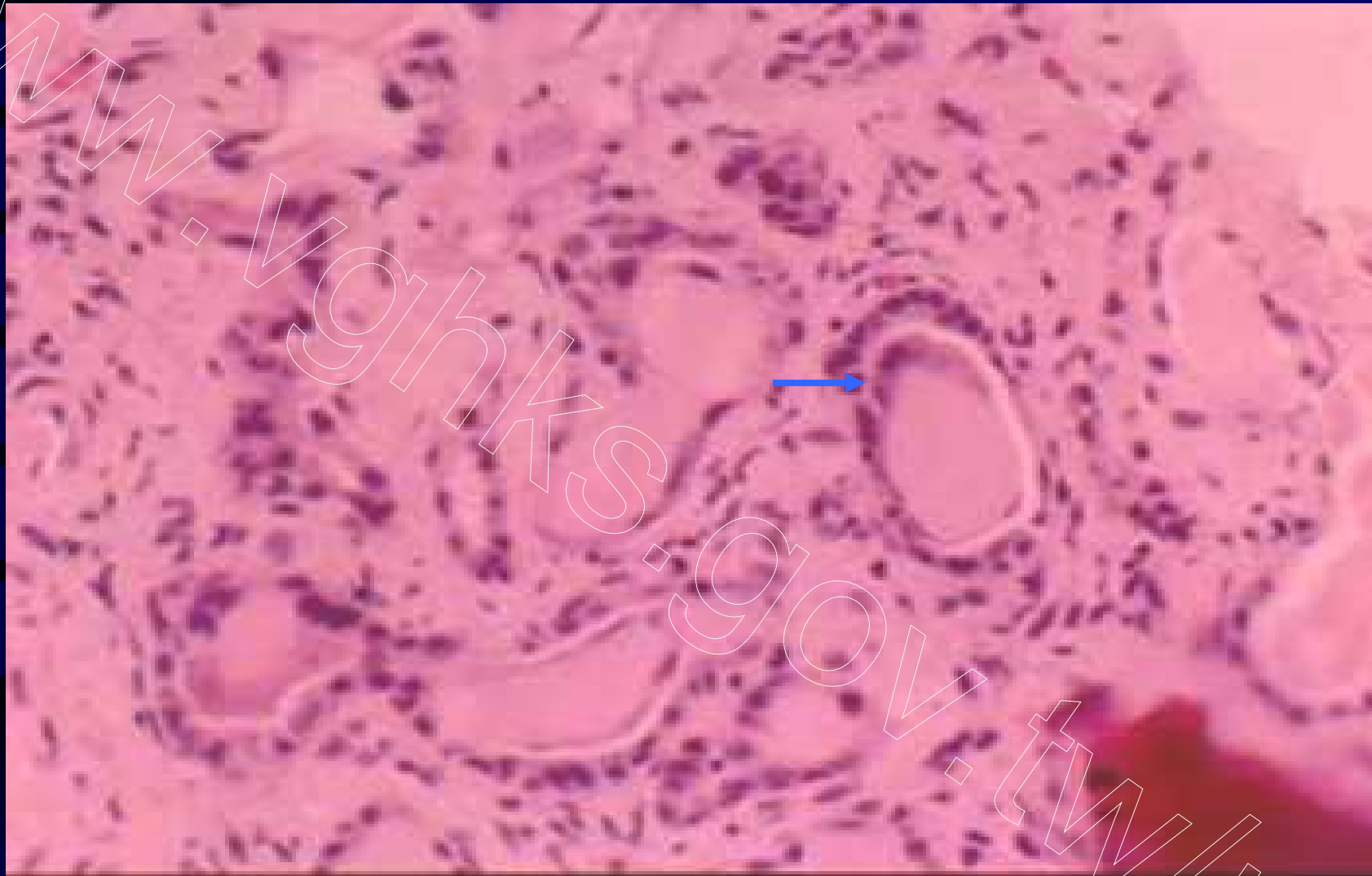


Fig 73. Diabetic glomerulopathy, exudative lesion, H&E



**Fig 74. Diabetic glomerulopathy, thick basement membrane,
TEM**



**Fig 75. Myeloma Kidney, giant cell reaction to tubular casts,
H&E**

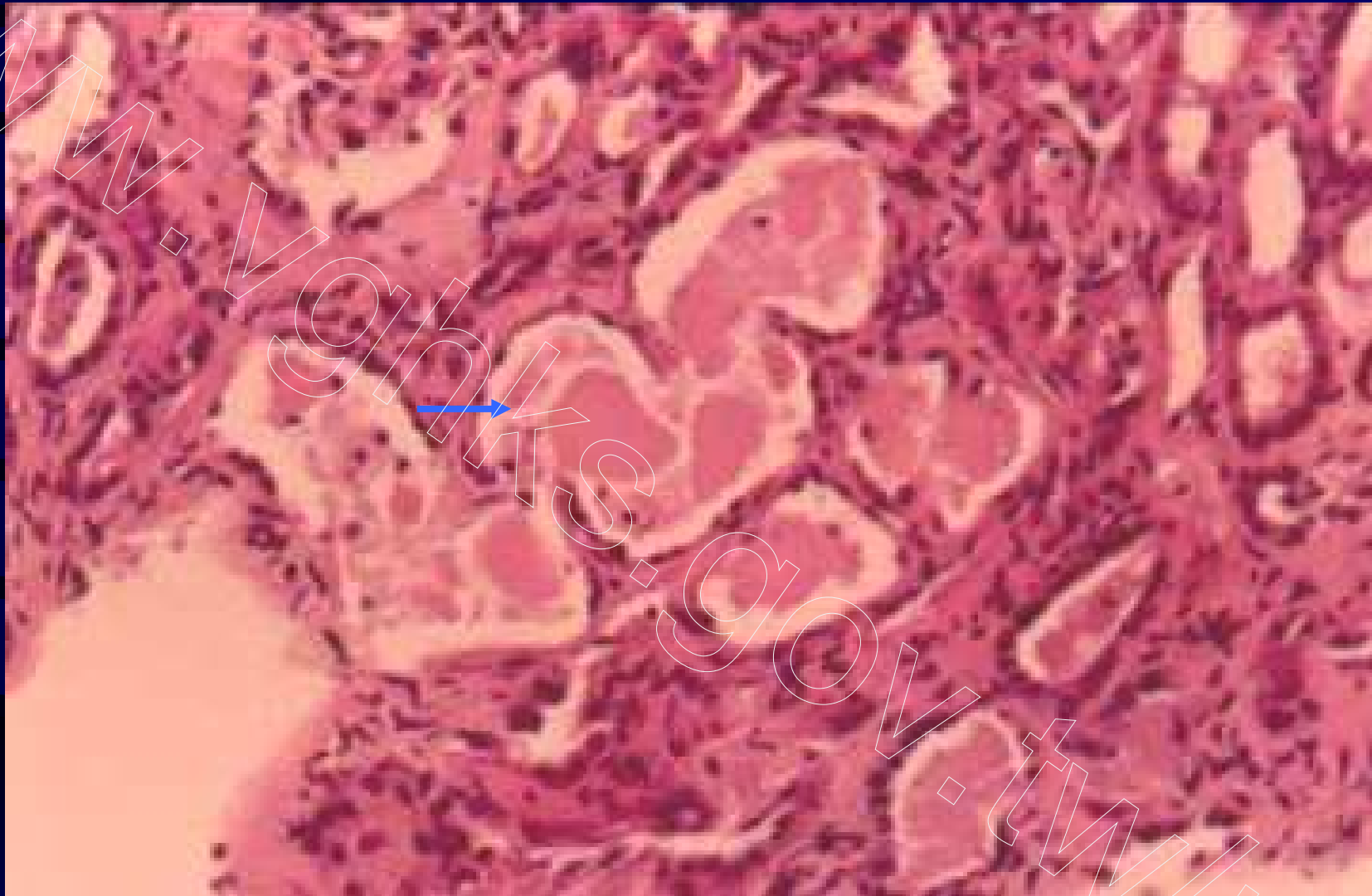


Fig 76. Myeloma Kidney, fragmented tubular casts, H&E

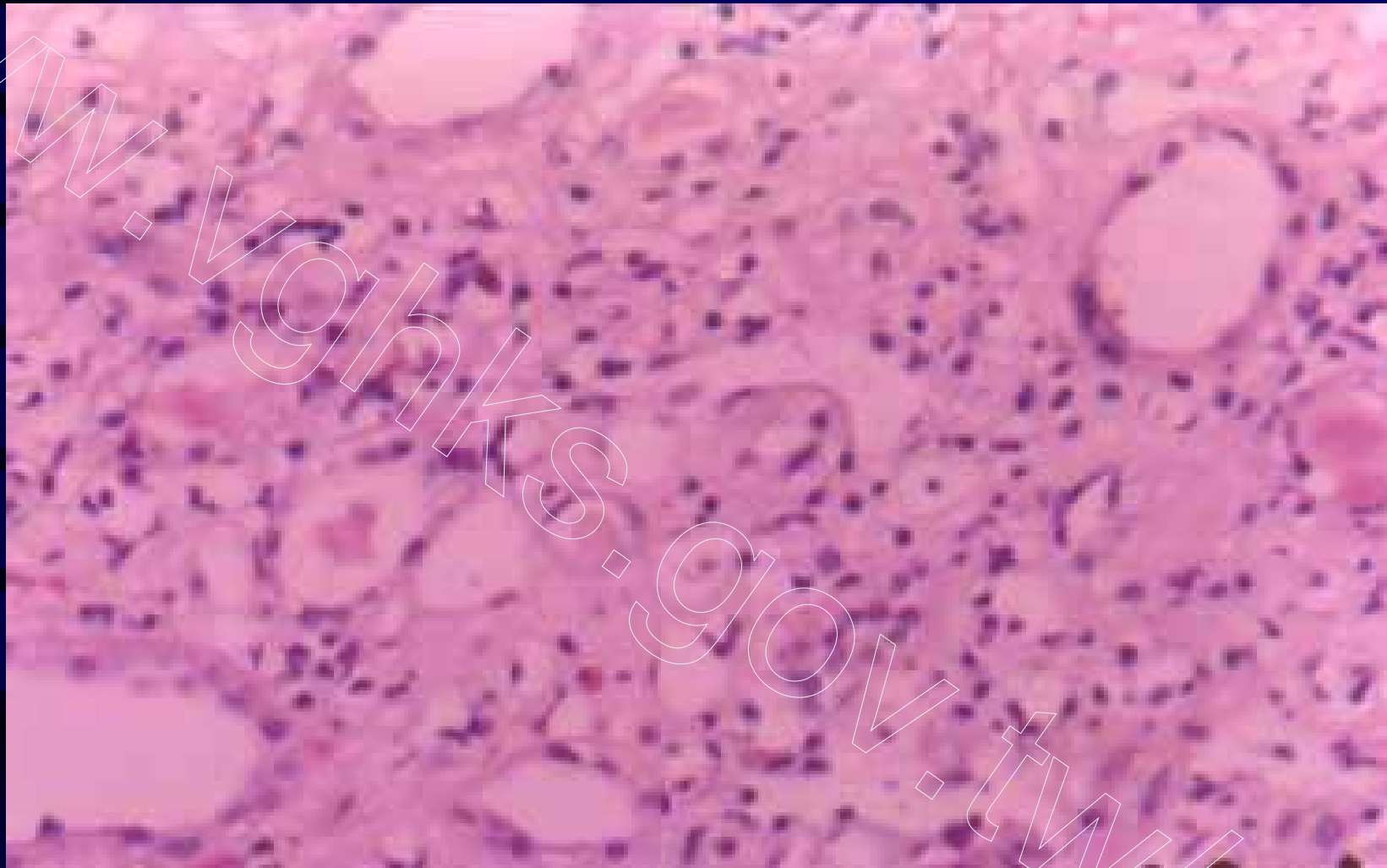


Fig 77. Acute interstitial nephritis, interstitial lymphocytes and eosinophils infiltrate, H&E

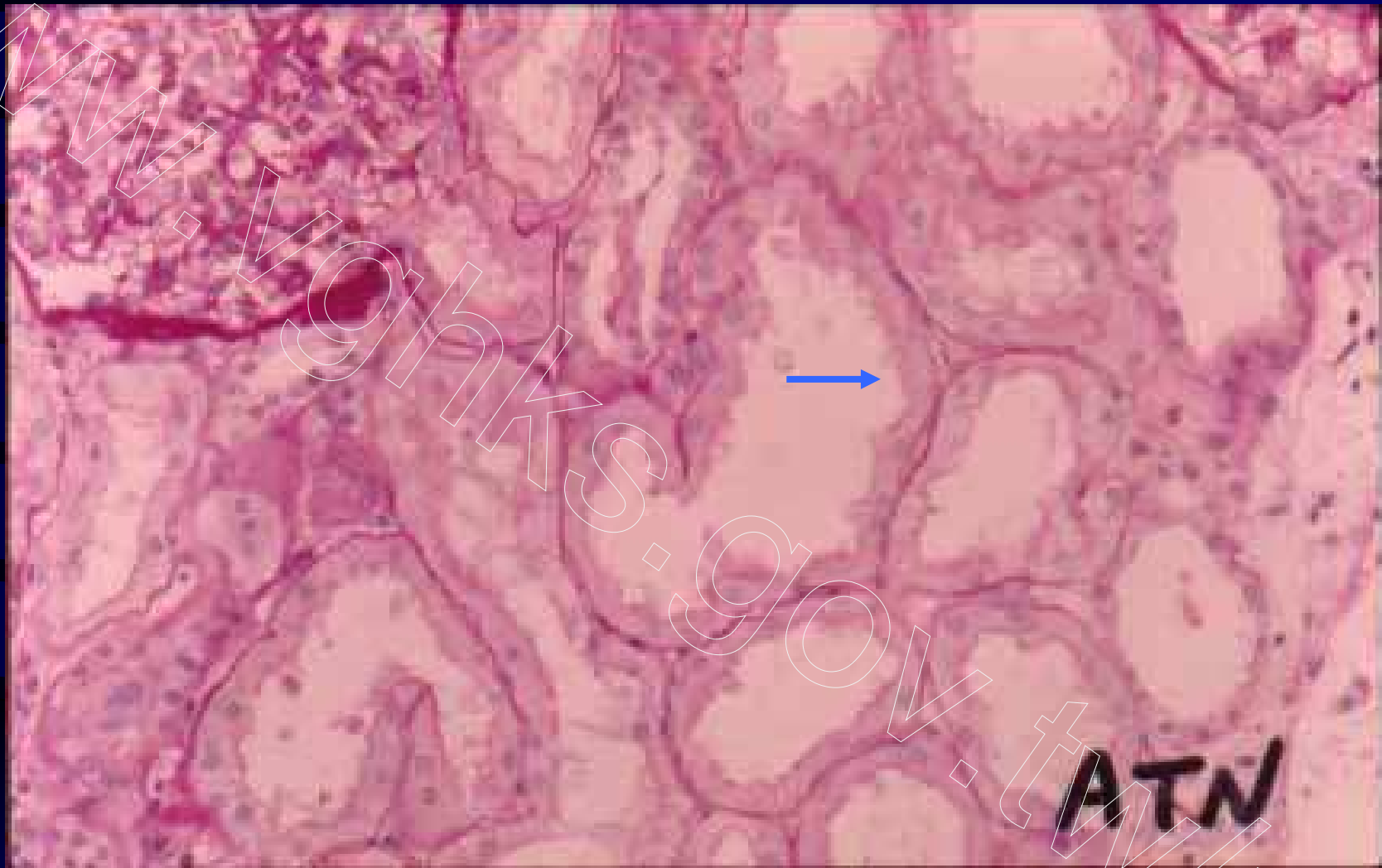


Fig 78. Ischemic acute tubular nephropathy (ischemic acute tubular necrosis), dilated tubules with attenuated brush border, PAS

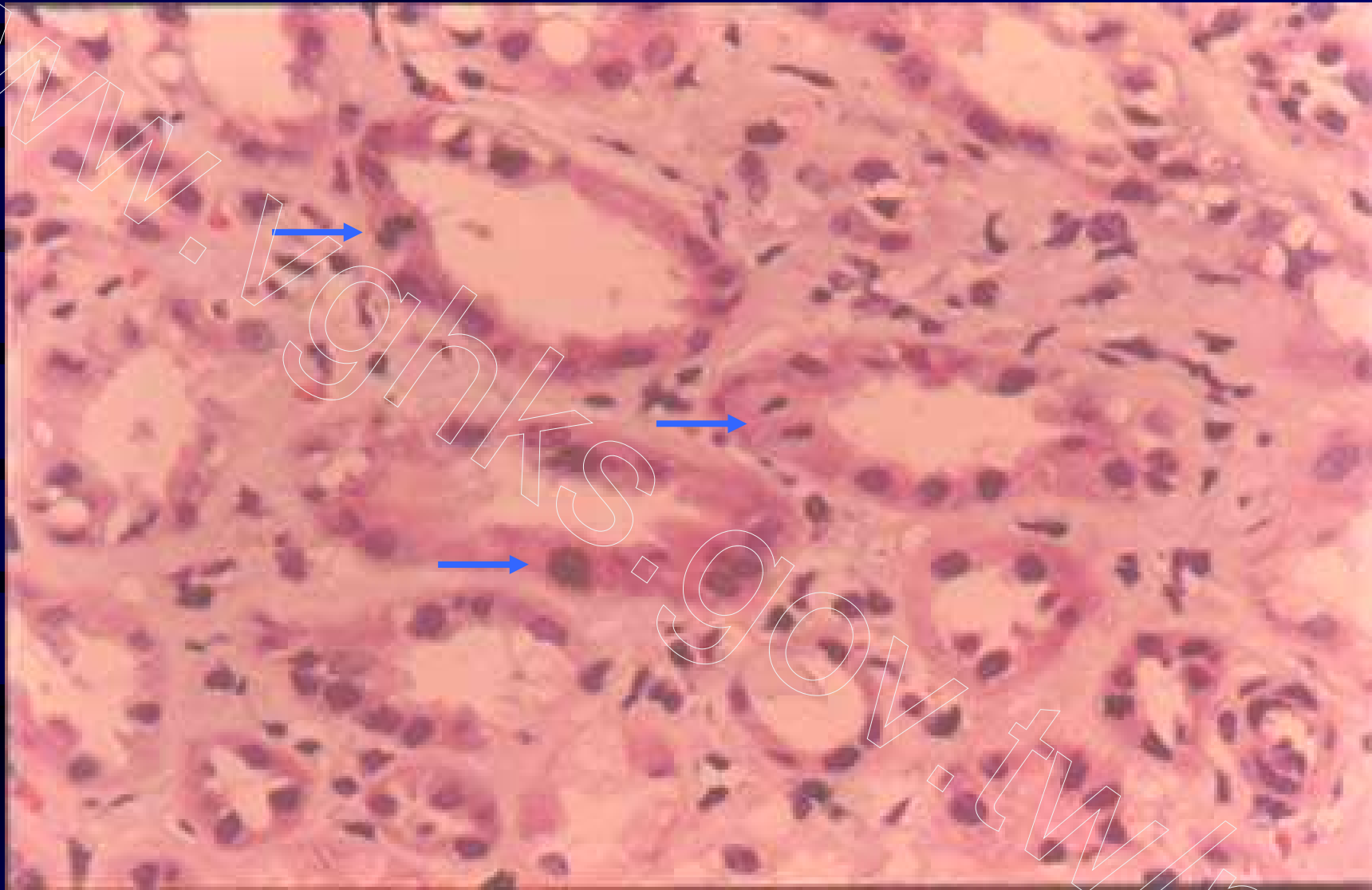


Fig 79. Ischemic acute tubular nephropathy, mitosis and regenerative atypia of tubular epithelial cells, H&E

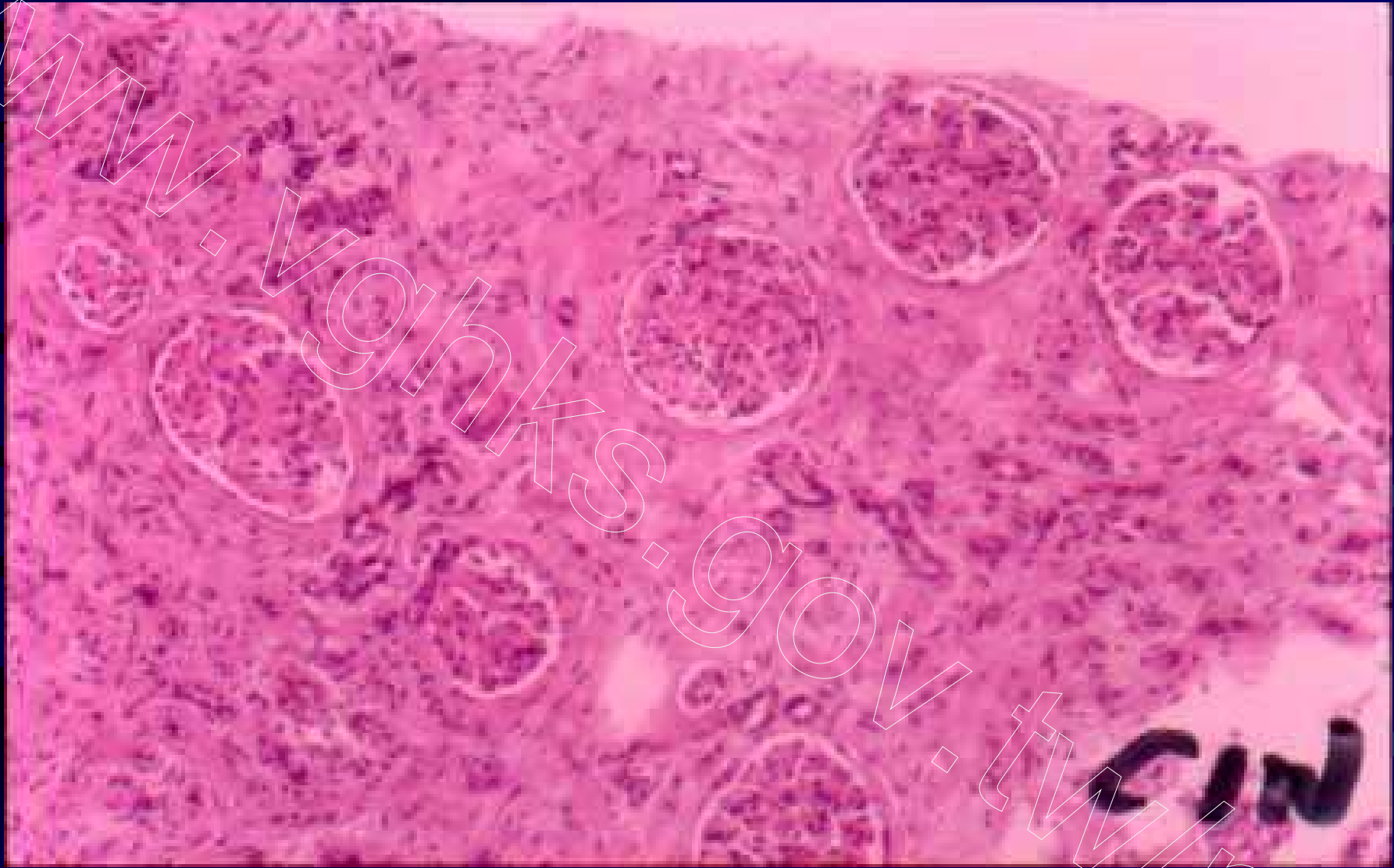


Fig 80. Chronic interstitial nephritis, marked interstitial fibrosis and tubular atrophy with preserved glomeruli, H&E