

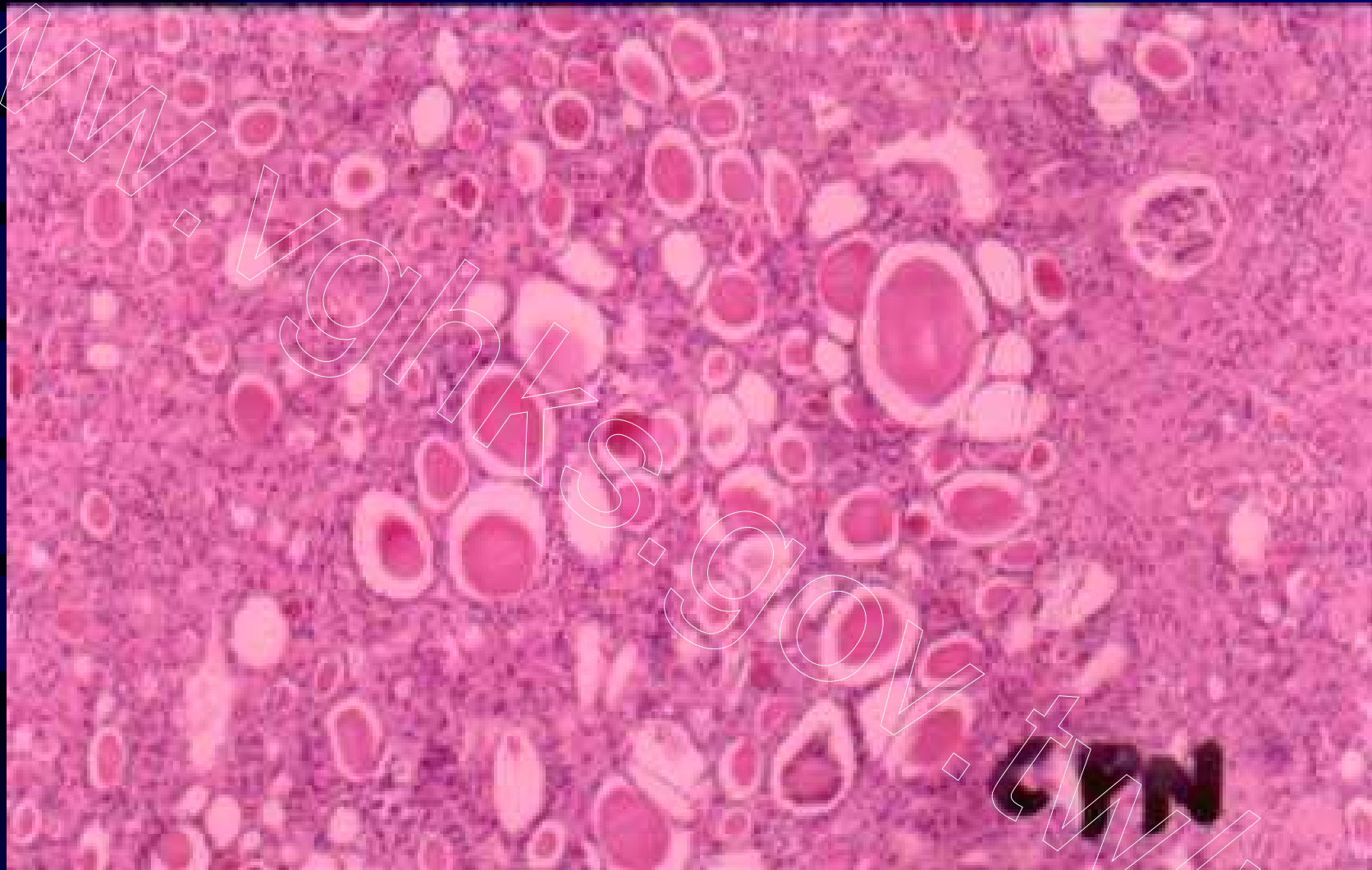Fig 81. Chronic pyelonephritis, thyroidization by intraluminal hyaline casts, H&E

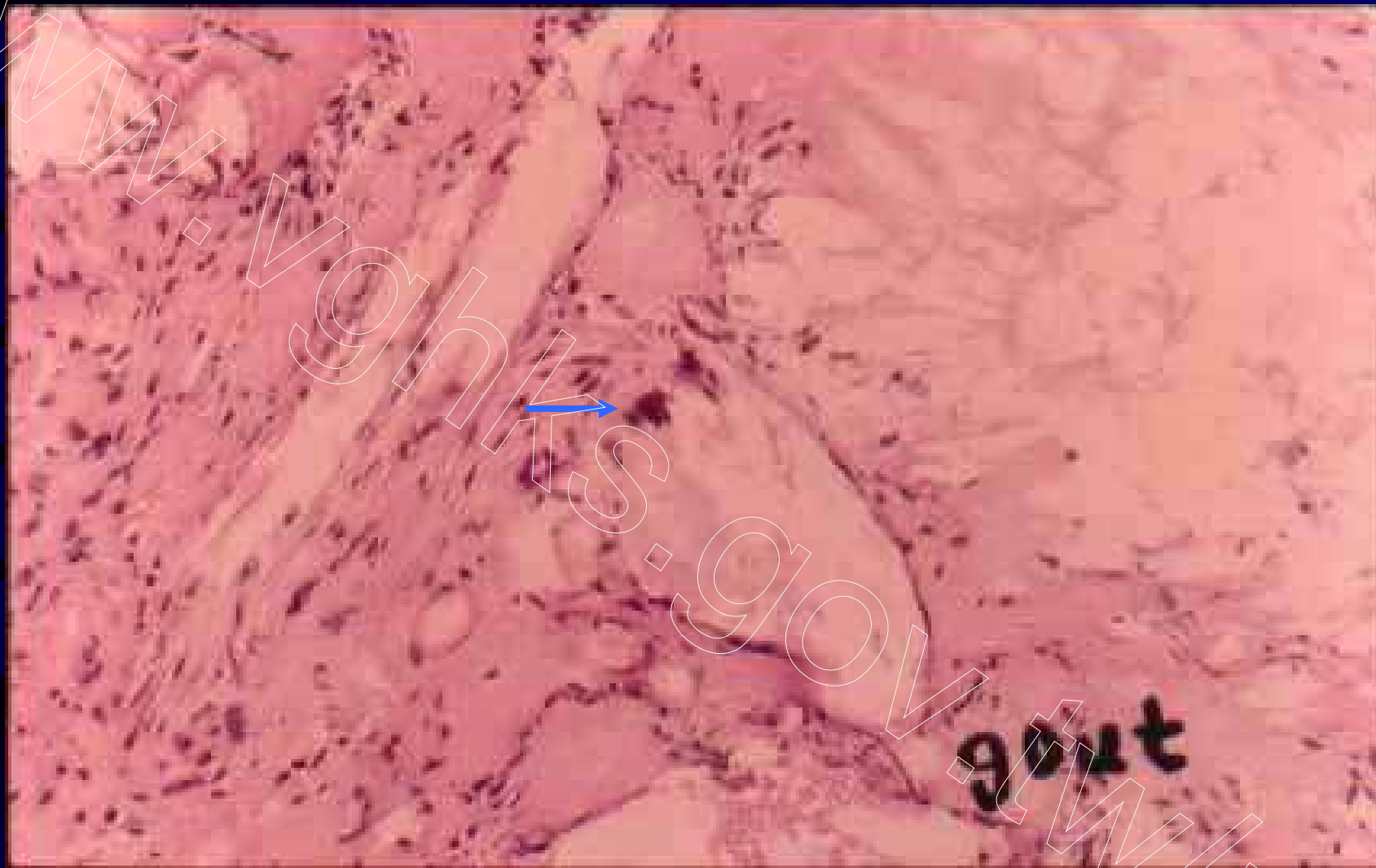

Fig 82. Gouty nephropathy, amorphous urate deposits with foreign body giant cell reaction, H&E

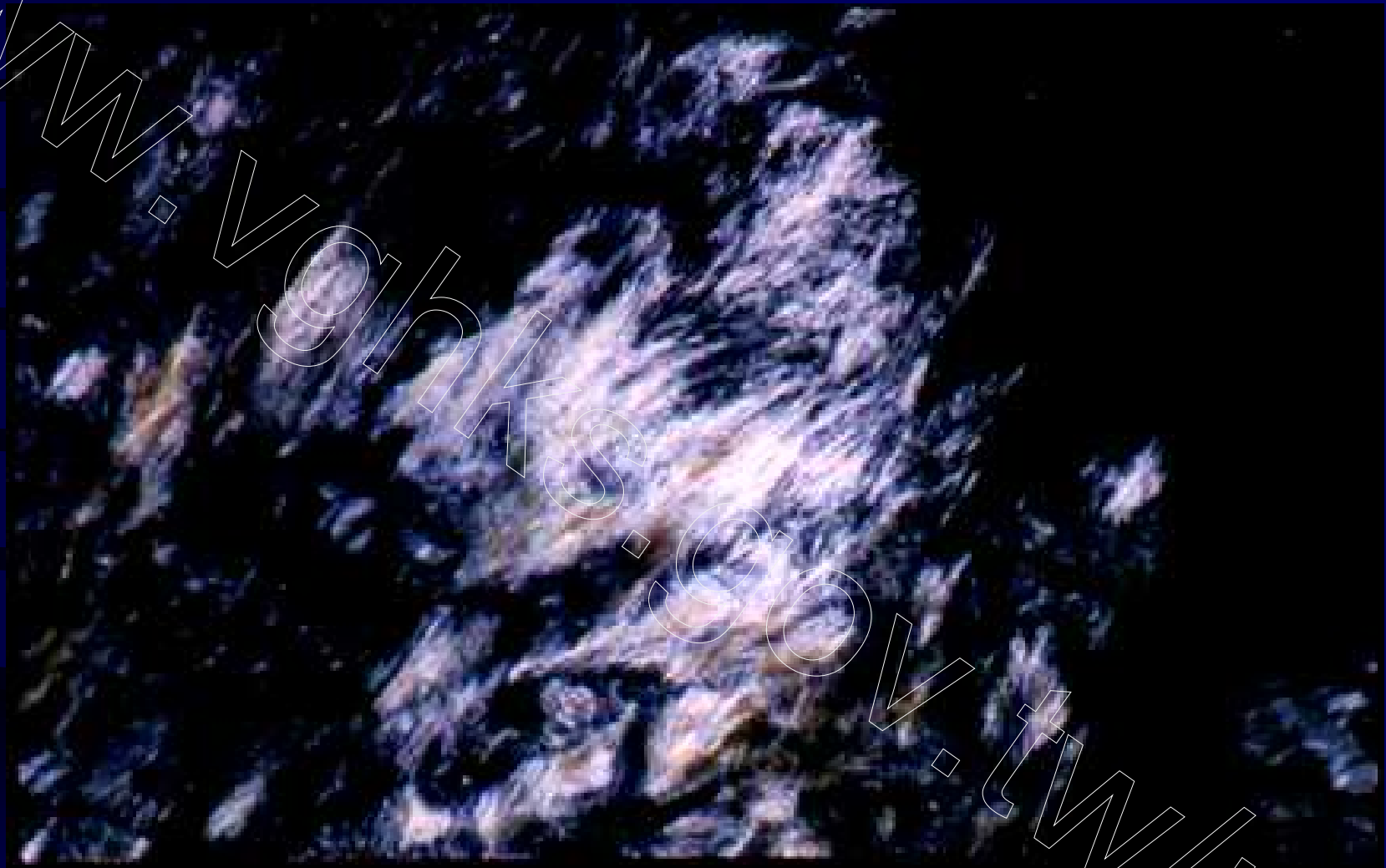

Fig 83. Gouty nephropathy, needle-shaped urate crystals, polarized lens

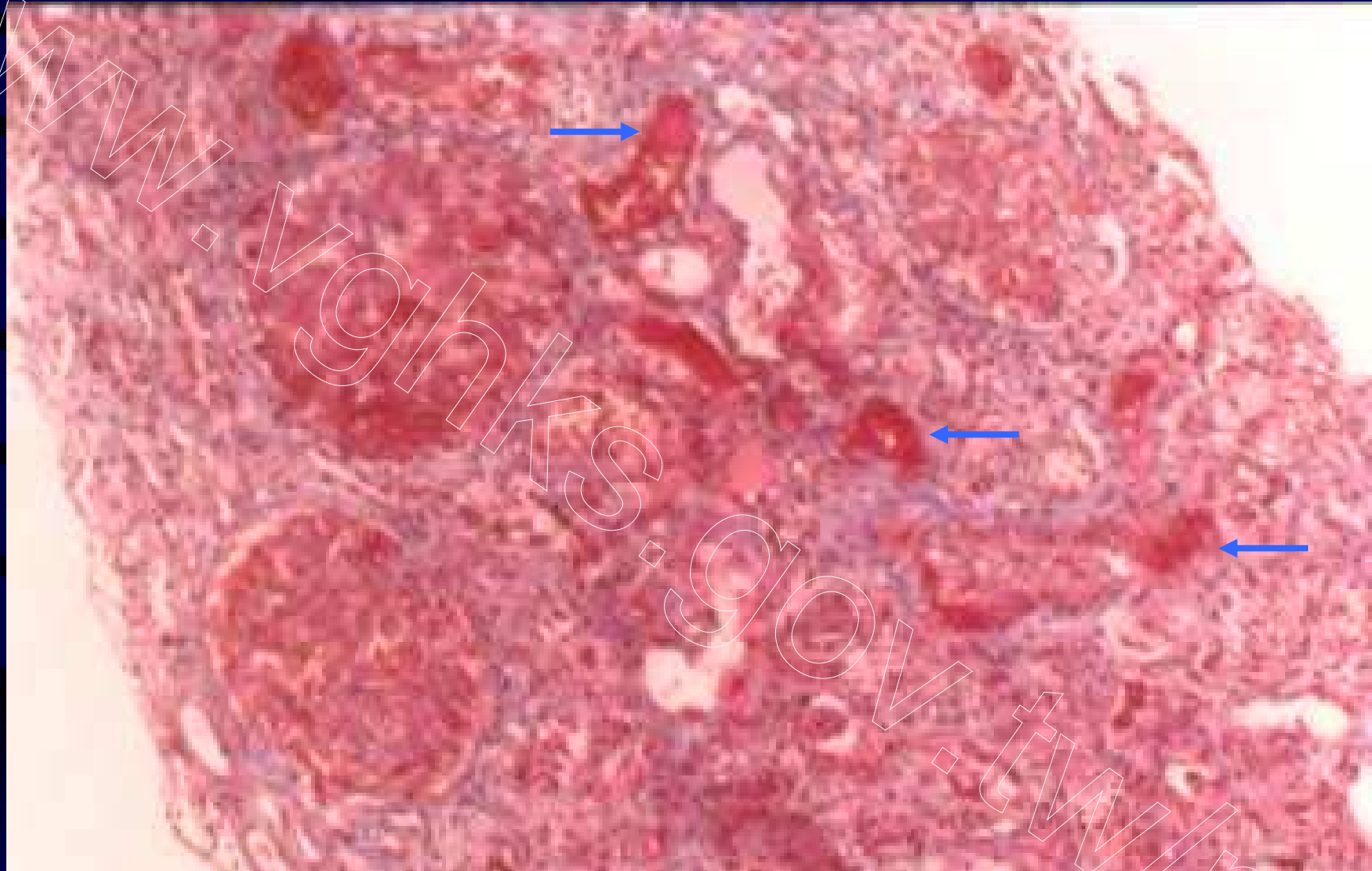


Fig 84. Necrotizing transplant vasculopathy, fibrinoid necrosis of arterioles, Masson trichrome

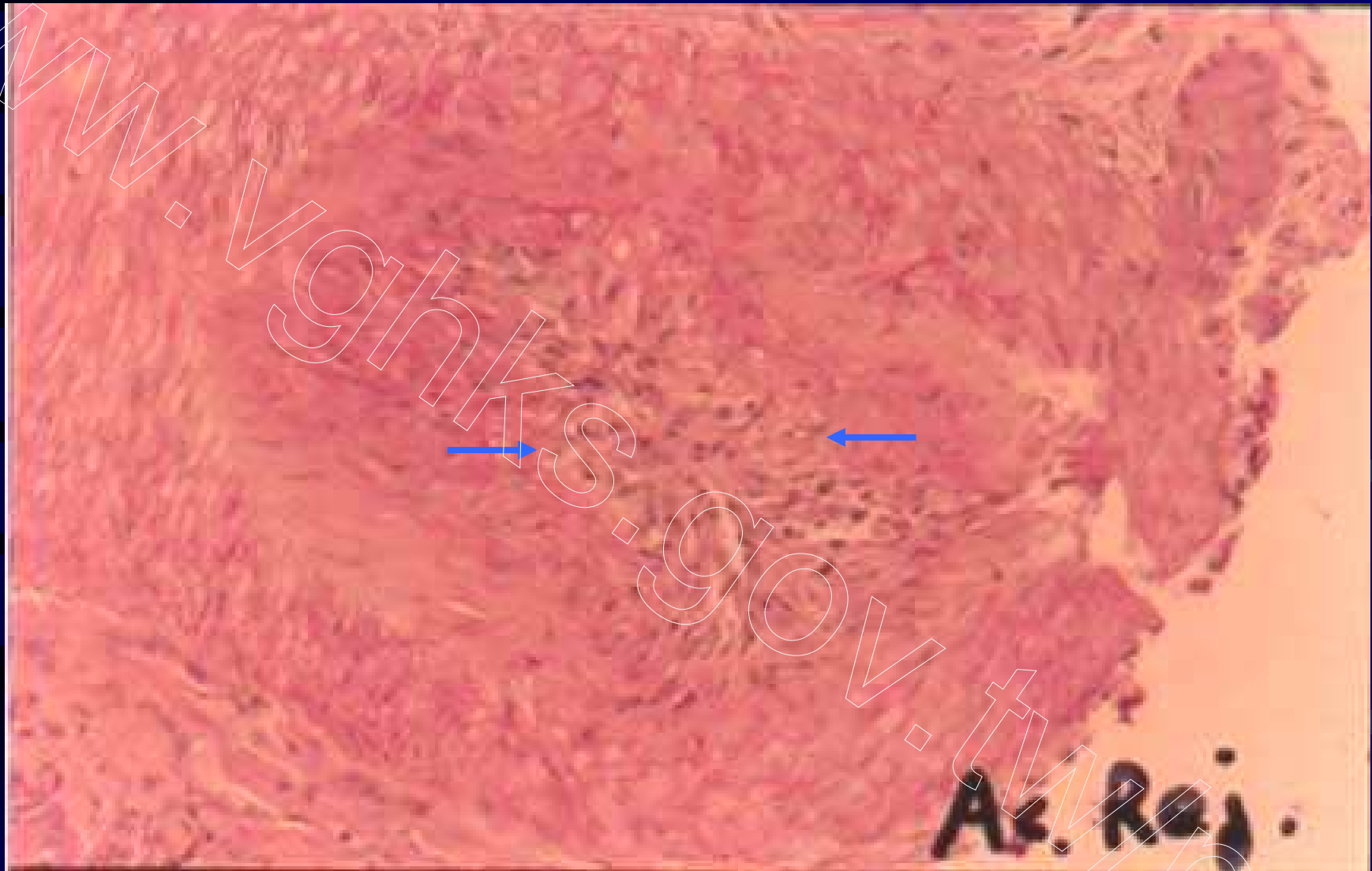


Fig 85. Infiltrative-proliferative transplant vasculopathy or intimal arteritis, Type II acute rejection (Banff 97), H&E

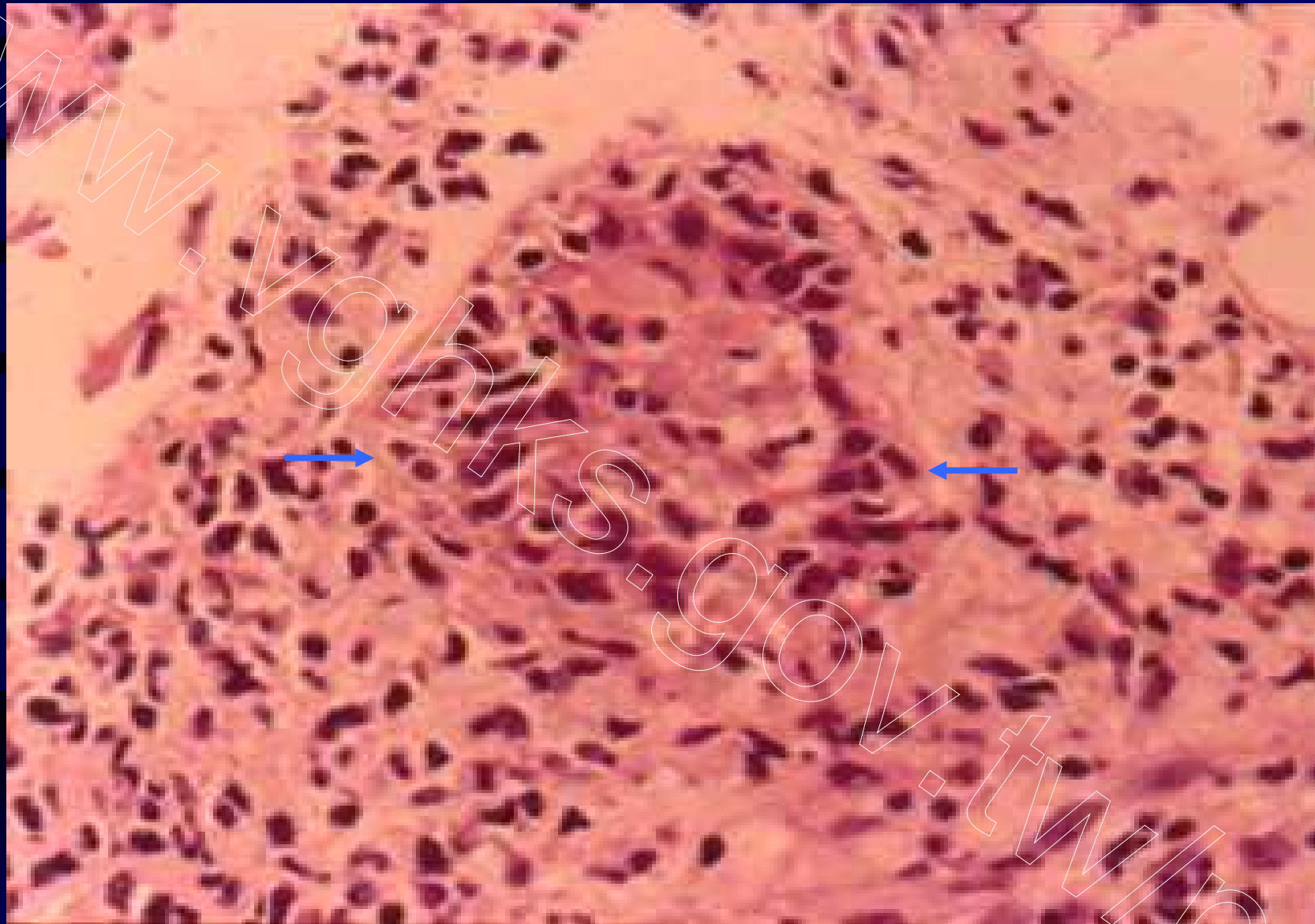
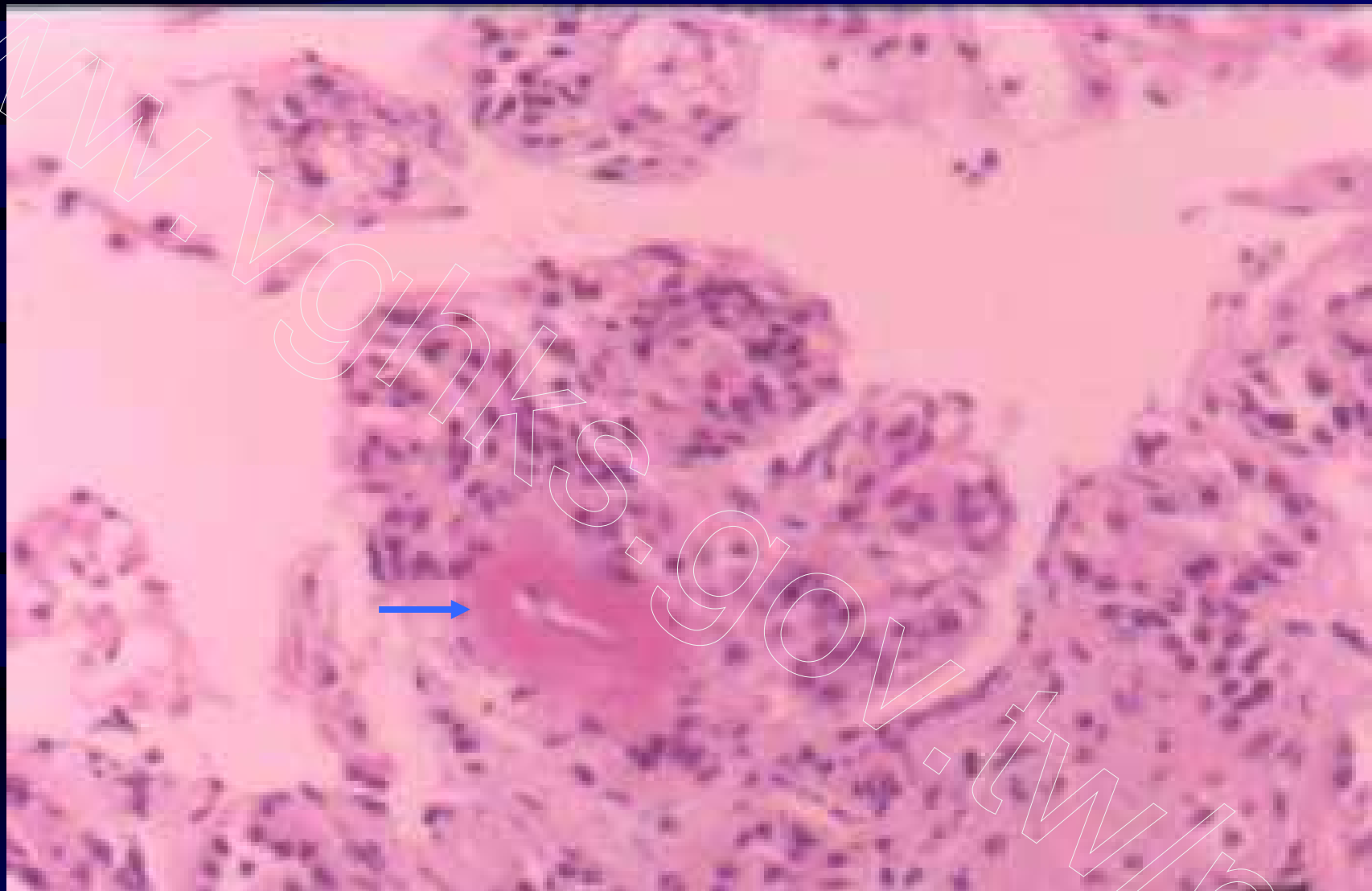


Fig 86. Tubulointerstitial cellular rejection, tubulitis, Type I acute rejection (Banff 97), H&E



**Fig 87. Lupus Nephritis, class IV, global endocapillary proliferation with arteriolar fibrinoid necrosis.
H&E**

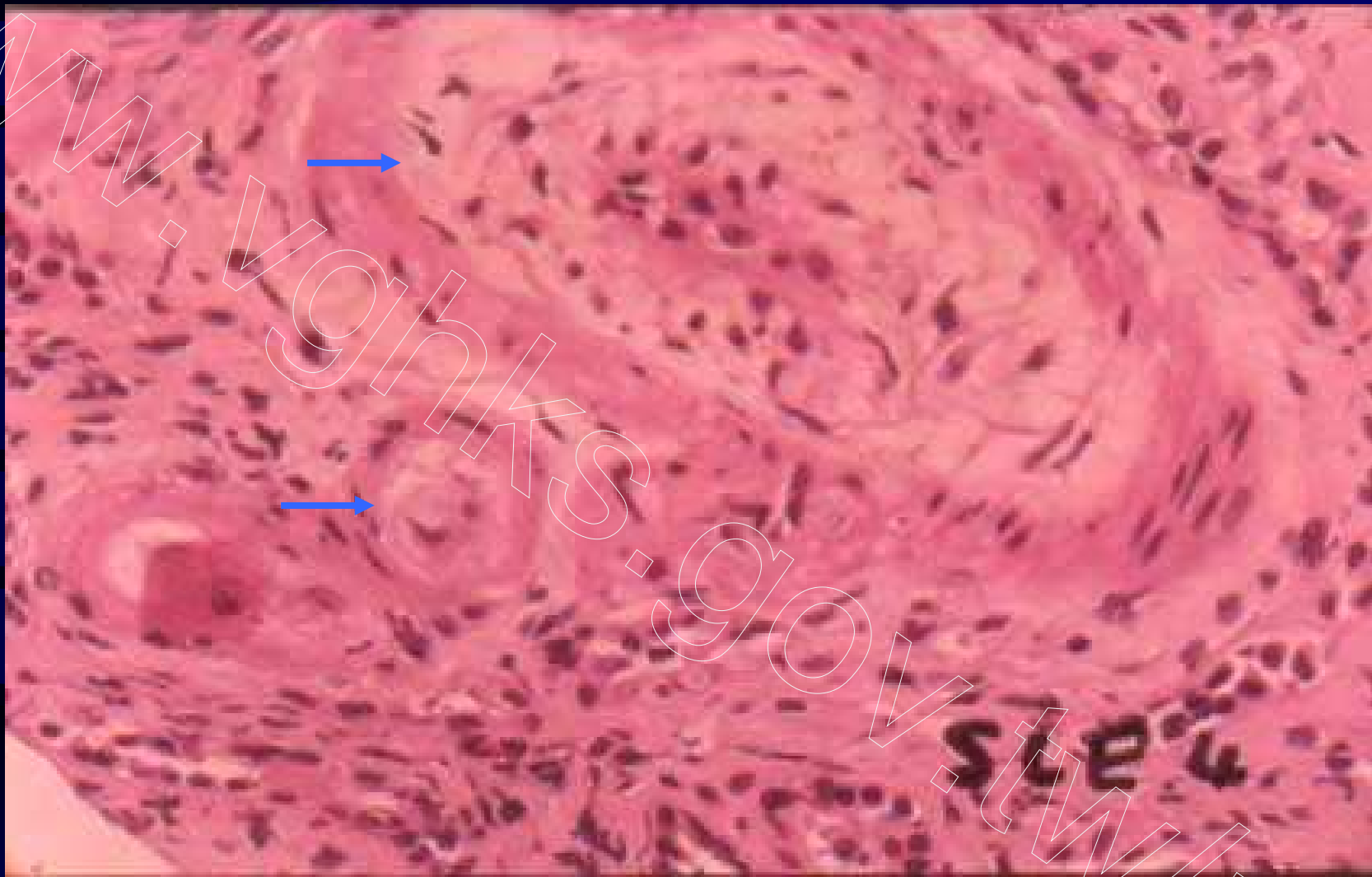


Fig 88. Lupus Nephritis, class IV, with fibromyxoid material within intima of artery and arteriole—changes suggestive of thrombotic microangiopathy. H&E

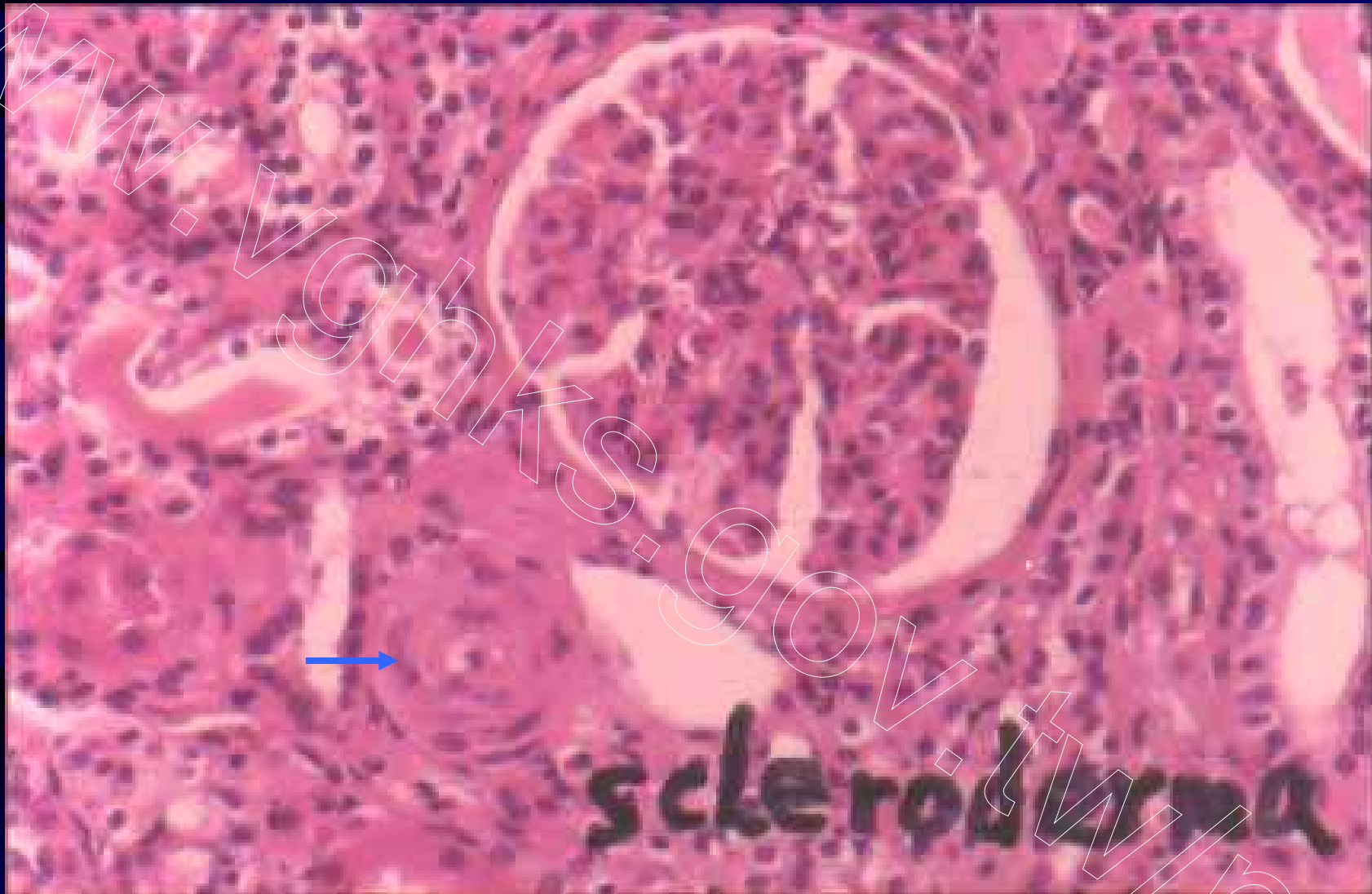

Fig 89. Scleroderma, ischemic collapsed glomerulus and onion-skin-like arteriole. H&E

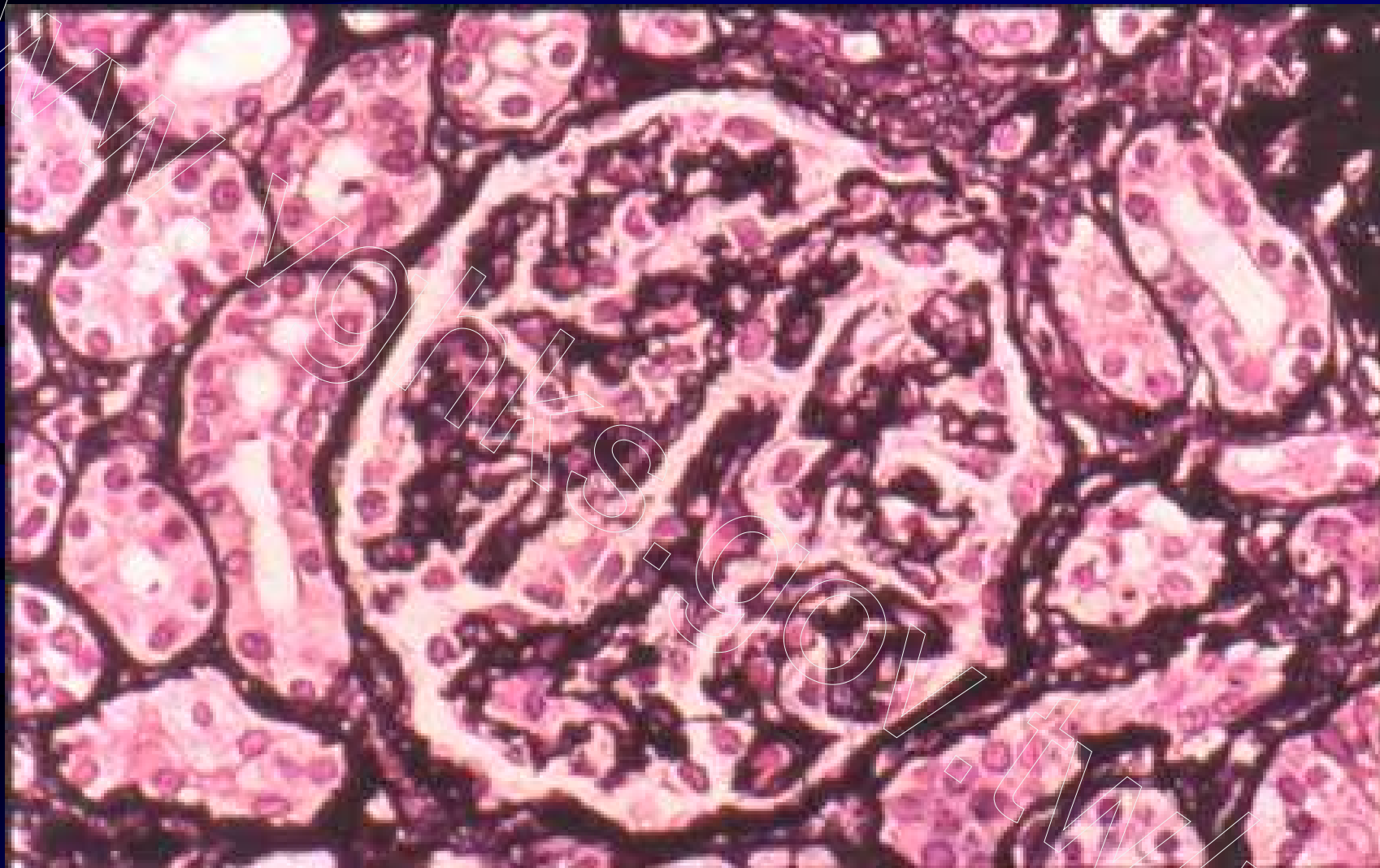


Fig 90. Scleroderma, ischemic wrinkling of collapsed glomerular capillary wall. PASM